



Journal homepage:
<http://www.bsu.edu.eg/bsujournals/JVMR.aspx>
 Online ISSN: 2357-0520 Print ISSN: 2357-0512



Original Research Article

Effects of bacterial lipopolysaccharide on serum testosterone level and sperm vitality in mature rats

Abdellah Hassan^a Mohammed Youssef^b Atef M. Khalil^c Hassan Ahmed^{b,*}

^a Department of Physiology, Faculty of Veterinary Medicine, Aswan University, Aswan, 81528, Egypt

^b Department of Physiology, Faculty of Veterinary Medicine, South Valley University, Qena 83523, Egypt

^c Department of Pathology and Clinical Pathology, Faculty of Veterinary Medicine, South Valley University, Qena 83523, Egypt.

ABSTRACT

In the last decades, the light had been shed on the importance of male reproduction and how to protect it from disease conditions and inflammation which may cause infertility. Accordingly, the mechanism underlying inflammation-mediated infertility must be well clarified. In the present study, an experimental model of acute inflammation in mature male albino rats was established by intraperitoneal (ip) injection of a single dose of lipopolysaccharides (LPS). Consequently, basic reproductive parameters were estimated after LPS administration. Blood samples were collected and assayed for serum testosterone levels. Semen was also analyzed for live sperm percent. Testes were removed for histopathological evaluation. The findings revealed that testosterone level in LPS-treated rats decreased significantly ($P < 0.05$) compared to control rats at 6 and 12 hrs after injection. Meanwhile, serum testosterone recovered 72 hrs after injection. Moreover, live sperm percent decreased drastically in LPS-treated rats ($P < 0.001$) compared with control rats at 6 and 12 hrs after LPS injection. Adverse effects of LPS on sperm vitality at 72 hrs after LPS injection were also found. Microscopic examination revealed that degenerative changes were observed in LPS-treated rats at 6 and 12 hrs. Most of histopathological findings returned to normal structure in LPS-treated rats at 72 hrs.

ARTICLE INFO

Article history:

Received: 11	2017
Accepted: 12	2017
Available Online: 12	2017

Keywords:

Lipopolysaccharides, testosterone, rats, semen, vitality, inflammation

* Corresponding author: Hassan Ahmed, Department of Physiology, Faculty of Veterinary Medicine, South Valley University, Qena 83523, Egypt. Email: hassan-younes@vet.svu.edu.eg

1. Introduction

The main testicular functions are steroidogenesis (testosterone production) and spermatogenesis. These biological processes are adversely affected during disease condition and inflammation leading to temporary or permanent infertility (Adamopoulos et al., 1978; Cutolo et al., 1988). Moreover, infertility is manifested by suppression of testosterone and sperm production as well as decrease percent of live sperm leading to low semen quality.

LPS is a bacterial endotoxin found in cell wall of gram negative bacteria which stimulates inflammatory response in several body organs including testes (Metukuri et al., 2010). The action of LPS is initiated through stimulation of Toll like receptor 4 (TLR4) in the plasma membrane of immune cells (Winnall et al., 2011). Subsequently, TLR4 induces several inflammatory products such as interleukin-1 β (IL-1 β), tumor necrosis factor- α (TNF- α), interferon- γ (INF- γ), and nitric oxide (NO) (Kern et al., 1995). These inflammatory products liberate reactive oxygen species (ROS) causing oxidative stress (Allen et al., 2004). Thereafter, high levels of ROS are the main cause of degeneration of primary and secondary spermatocytes as well as Leydig's cells (Fraczek and Kurpysz, 2005). Furthermore, the effects of LPS on testicular function were varied according to dose and period of administration. Chronic inflammation due to administration of LPS at low dose had no effect on testosterone level but had impairment effect on spermatogenesis (Kajihara et al., 2006). However, Acute LPS administration (single injection) with high dose revealed damage of both testosterone and sperm production by degeneration of Leydig and germ cells (Metukuri et al., 2010).

The aim of this study well understands the effect of single dose of LPS serum testosterone level and sperm vitality by adoption of experimental model of LPS-induced inflammation in adult male rats.

2. Materials and methods

Animals

Forty adult male Wister rats weighing 160 \pm 20 g were purchased from the lab animal house, Faculty of Medicine, Assuit University, Assuit. Rats were transferred to animal physiology department, Faculty of Veterinary Medicine, South Valley University,

Qena. They were housed in clean plastic cages and maintained on a 12 h light/dark cycle and at temperature of 22 \pm 2 °C with *ad libitum* access to food and water for two weeks to be acclimatized laboratory environment. During acclimatization period, rats were handled daily for 5min to acclimate them to human contact and to decrease any hypothalamo-pituitary- adrenal axis responses to the handling involved in the subsequent experimental manipulations (Ma and Lightman, 1998).

Reagents

LPS from *E. coli*, O111:B4 serotype was Purchased from Sigma Chemical Company (St Louis, MO, USA). LPS was daily freshly prepared by dissolving into a pyrogenic and sterilized saline (0.9% NaCl).

Experimental design

Rats were randomly allocated into two groups (20 rats for each); each group subdivided into four subgroups (5 rats for each). Group I (control); rats were injected with saline (0.9% NaCl at dose (0.1 ml/kg BW, ip) and group II (LPS-treated); rats were injected with a single dose of LPS (1mg /kg B.W, ip) (Huang et al., 2007).The injection was started at 8:00 am.

Samples collection

Blood samples were collected 6, 12, and 72 hours respectively from each subgroup, rats were anesthetized with sodium thiopental (50 mg/kg BW, ip) then slaughtered. Testes and epididymal semen samples were collected by squeezing. Sera were separated and collected in Eppendorf tubes and kept after collection at -80°C until assay of serum testosterone level. Testes were kept in neutral buffered paraformaldehyde 4% for histopathological processing.

Hormone assay

Serum testosterone levels were measured using enzyme-linked immunosorbent assay (ELIA) kits according to manufacturer's instructions (Calbiotech, El Cajan, CA, USA). Hormonal assay was done by microplate reader (Infinit 50, Männedorf, Switzerland) at wave length 450 nm (Chen et al., 1991).

Sperm vitality

Immediately after epididymal semen collection, semen was diluted (1:10) using 0.9% NaCl. Live sperms percent was estimated as previously described (WHO, 2010).

Histopathological examination

Testes of both control and LPS-treated rats of the experimental groups was removed and quickly fixed in neutral buffered paraformaldehyde 4%, processed through the conventional paraffin embedding technique (Bancroft and Gamble, 2002), sectioned at 5 µm thick and stained with haematoxylin and eosin (HE).

Statistical analysis

Results were analyzed statistically by Graphpad prism 5 and Excel 2010 software. Data were expressed as mean ± standard error (SE) and differences between groups were analyzed by using *T-Test*. Values of $P<0.05$ and $P<0.001$ and were considered significant compared with control.

3. Results

Level of serum testosterone

The testosterone levels in LPS-treated rats were significantly decreased ($P<0.05$) (1.5 ± 0.2 and 1.1 ± 0.2 ng/ml) compared with control (4.1 ± 0.2 and 3.2 ± 0.8 ng/ml) at 6 and 12 hrs respectively (Fig. 1). However, after 72 hrs, testosterone level increased again (3.7 ± 0.7 ng/ml) nearly to control level (2.9 ± 0.6 ng/ml) respectively.

Live percent

Live sperm percent decreased after LPS injection, this decrease was highly significant ($P<0.001$) throughout experimental period. After 6 hrs, live sperm percent was lowered from (93.3 ± 1.1) in control group to (80.4 ± 1.7) in LPS-treated rats. Also, 12 hrs after LPS injection the vital sperms lowered from (95.2 ± 0.5) in control to (84.4 ± 0.9) in LPS-treated rats. The adverse effect of LPS on live sperm percent was extended to 72 hrs after LPS injection and decreased from (93.4 ± 0.5) in control group to (81.1 ± 2.0) in LPS-treated rats respectively (Fig. 2).

Microscopic examination

Testes in control rats revealed normal histological structure (Fig. 3A-C). Seminiferous tubules contain normal Sertoli's cells, primary and secondary spermatocytes, spermatids as well as elongated spermatozoa in the center. Moreover, interstitial or Leydig's cells were normally distributed between seminiferous tubules. Regarding to LPS treated rats, the adverse effects of LPS on the testes was more prominent after 6 and 12 hrs from injection. After 6 hrs seminiferous tubules showed necrosis of lining epithelial cells, degeneration of primary and secondary spermatocyte. In addition, basement membrane detached from underlying tissue with vacuolation of Sertoli's cells. Moreover, there was necrosis of Leydig's cells accompanied by interstitial edema (Fig. 3D). The deleterious effect of LPS on testes was still prominent 12 hrs after LPS injection. Seminiferous tubules showed sever necrosis in the lumen with degeneration of primary spermatocyte and vacuolation of Sertoli's cells (Fig. 3E). Although some adverse effect such as degeneration and vacuolation in seminiferous tubules was observed after 72 hrs, recovery became more prominent in wide parts of testes indicated by increase number of Sertoli's cells, primary and secondary spermatocytes and newly formed spermatids (Fig. 3F).

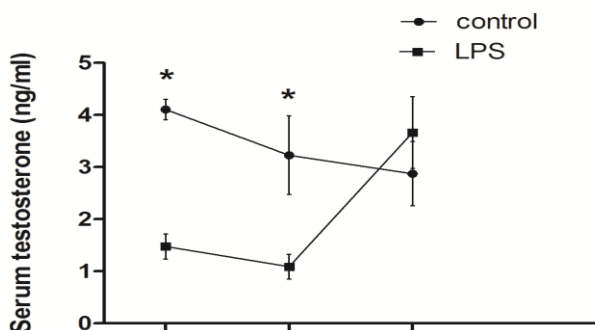


Fig.1. Level of serum testosterone in control and LPS-treated animals in different time points. Values are expressed as Mean ± SE, for control and LPS-treated rats n=5at 6, 12, and 72 hrs. (*: $P<0.05$).

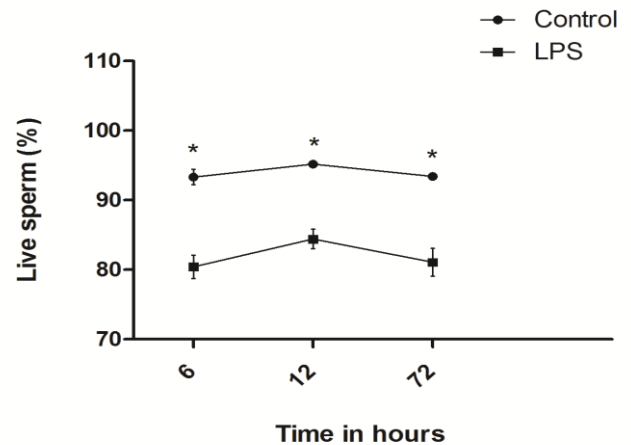


Fig. 2. Live sperm percent in control and LPS-treated animals at different time following LPS injection. Values are expressed as Mean±SE, for control and LPS-treated rats n=5 at 6, 12, and 72 hrs. (*: $P<0.001$).

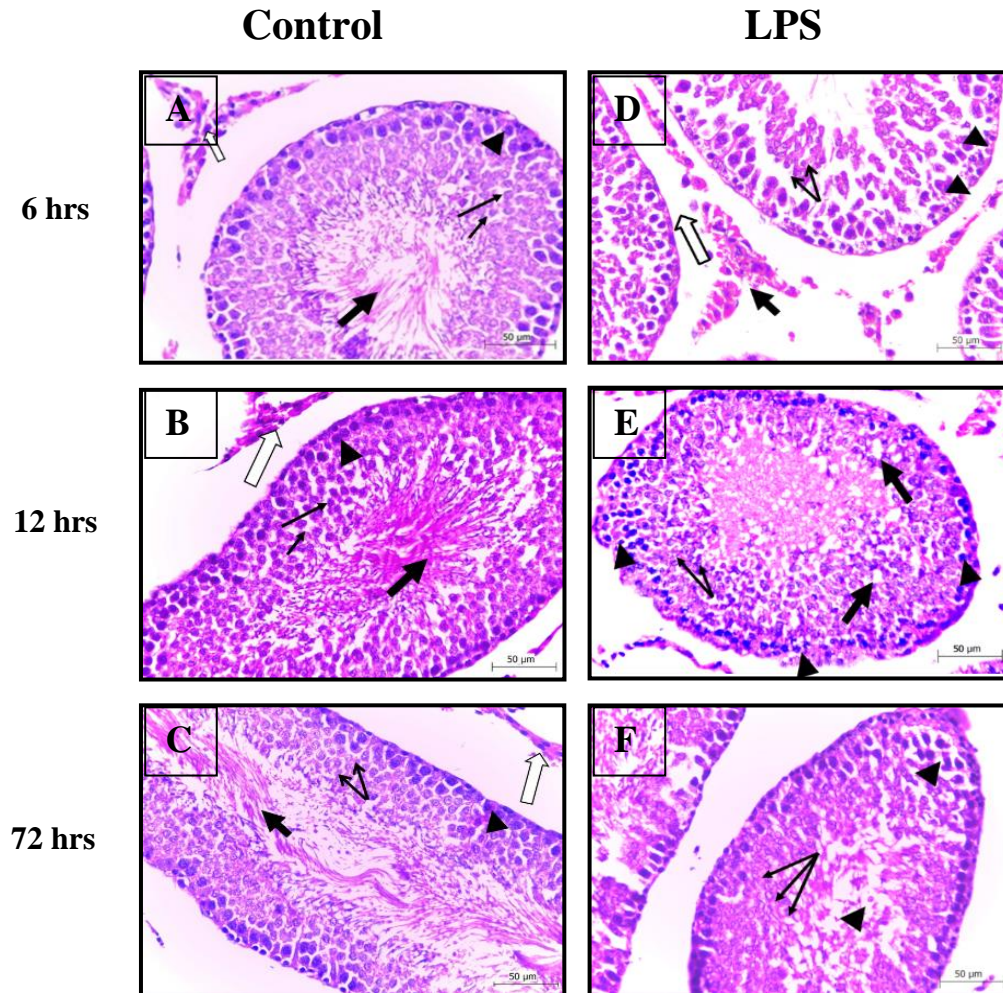


Fig. 3. Testicular histological and histopathological sections of normal and LPS-treated rats. A-C) Normal testes histological structure including seminiferous tubule with Sertoli's cells (arrow head), primary and secondary spermatocyte (thin arrow) and spermatozoa (thick arrow) with normal Leydig cells (hollow arrow). D-F) LPS-treated animals at 6, 12, and 72 hrs after injection. D) Photomicrography of testis after 6 hrs from LPS injection showing interstitial odema between the seminiferous tubules (hollow arrow) with necrosis of Leydig's cells (thick arrow) and vacuolation in the Sertoli's cells area (arrow head) associate with moderate degeneration in the primary and secondary spermatocytes (thin arrow). (E) photomicrograph of testis after 12 hrs of LPS injection showing severe degeneration in the seminiferous tubule characterized by vacuolation in the Sertoli's cells (arrow heads) and in between the epithelium and lumen of the seminiferous tubules (thick arrow) accompanied by mild necrosis in the spermatocytes (thin arrow). (F) Testis after 72 hrs of LPS injection showing degeneration in the seminiferous tubules characterized by vacuoles observed between the spermatocytes (arrow head) and in the lumen of the tubule. Also, there is an increase in the number of spermatocytes and Sertoli's cells with low number of newly formed spermatids (thin arrow). (HE HE, Scale bar= 50 μ m).

4. Discussion

The aim of present study to investigate of LPS single dose on serum testosterone level and sperm vitality. It is found a deleterious effect of LPS is varies according to time course of injection. LPS reduced serum testosterone level 6 and 12 hrs after injection which was the parallel to the findings recorded by Danek (2003). Who found that serum testosterone level of stallion was decreased 6-24 hrs after LPS injection with different doses compared with current experiment. However, in both studies serum testosterone level was completely recovered 72 hrs after LPS injection due to fading out the LPS-induced inflammation. On the other hand, chronic effect of LPS injection at lower dose (0.1 mg/kg BW) with multiple injections revealed no effect on serum testosterone level 24 hrs and one week after injection (Kajihara et al., 2006). While, both acute and chronic treatment of LPS had low semen quality effect as well as impairment of normal histological structure of testes. The main mechanism of LPS-adverse effect on testes and semen was due to LPS-induced inflammation which causes oxidative stress and imbalance between ROS and antioxidant (Allen et al., 2004; Reddy et al., 2006; Lei et al., 2013). Impairment effect of oxidative stress on testes due to damage of germ and Leydig's cells reducing both sperm vitality and testosterone level (Adel et al., 2009; Metukuri et al., 2010; Al-Olayan et al., 2014). Moreover, there is a direct relationship between inflammatory mediators such as cytokines and interleukine-6 which are elevated after LPS injection (Jegou et al., 1995) and oxidative stress by increasing level of superoxide anions (O_2^-) and hydrogen peroxide (H_2O_2) (Wang et al., 1997; Ochsendorf, 1999). Beside inflammatory mediators and elevation of ROS, apoptosis also is one cause of testicular function impairment and semen quality loss associated with permanent infertility due to germ cells apoptosis (Fraczek and Kurpisz, 2005). Biochemical mechanism of LPS-damage effect on testes due to an increase in free radicals that is highly sensitive to high level of lipid peroxidase (Bergendi et al., 1999). Therefore, leading to irreversible impairment of mitochondrial functions such as mitochondrial respiration, oxidative phosphorylation and transport (Bacon and Britton, 1990) ending with germ or Leydig's cell death. The most recent published results found that LPS decreased sperm intracellular cAMP *in vitro* leading

to deleterious effect on sperm vitality by increasing dead sperm percent (Li et al., 2016).

5. Conclusion

The present study concluded that LPS-induced inflammation leading to testosterone production and semen life sperm percent. Serum testosterone level decreased significantly 6 and 12 hrs after LPS injection. However, its level recovered after 72 hrs. Microscopic examination revealed those more degenerative changes in Sertoli's cells, primary & secondary spermatocytes, spermatids, spermatozoa and Leydig's cells at 6 and 12 hrs. Most of histopathological parameters returned to normal structure in LPS-treated rats at 72 hrs.

Acknowledgement

This work was supported by Grant NO. 2505 funded by Science & Technology Development Fund, Egyptian Ministry for Scientific Research, Egypt.

References

- Adamopoulos DA, Lawrence DM, Vassilopoulos P, Contoyiannis PA, Swyer GIM (1978). Pituitary-testicular interrelationships in mumps orchitis and other viral infections. *Br. Med. J.*, 1:1177–1180.
- Adel RA, Gouda KH, Abdulaziz AA, Abdulaziz MA, Salim SA, Saleh AA (2009). Pro-inflammatory and oxidative stress pathways which compromise sperm motility and survival may be altered by L-carnitine. *Oxid. Med. Cell Longev.*, 2: 73–81.
- Allen JA, Diemer, T, Janus P, Hales KH, Hales DB (2004). Bacterial endotoxin lipopolysaccharide and reactive oxygen species inhibit Leydig cell steroidogenesis via perturbation of mitochondria. *Endocrine.*, 25: 265–275.
- Al-Olayan M, El-Khadragy F, Metwally M, Moneim A (2014). Protective effects of pomegranate (*Punica granatum*) juice on testes against carbon tetrachloride intoxication in rats. *BMC Complement Altern Med.* 14: 164.
- Bacon BR, Britton RS (1990). The pathology of hepatic iron overload: a free radical-mediated process? *Hepatology* 11: 127–137.
- Bancroft J D, Gamble M (2002). Theory and practice of histological techniques. 5th. ed.

- Edinburgh. Churchill Livingstone Pub., pp 593–620.
- Bergendi L, Benes L, Durackova Z, Ferencik M (1999). Chemistry, Physiology and Pathology of free radicals. *Life Sci.*, 65: 1865–1874.
- Chen A, Bookstein JJ, Meldrum DR (1991). Diagnosis of a testosterone-secreting adrenal adenoma by selective venous catheterization. *Fertil. Steril.*, 55: 1202–1203.
- Cutolo ME, Chan MK, Movat HZ (1988). Sex hormone status of patients with rheumatoid arthritis: evidence of low serum concentrations at baseline and after human chorionic gonadotrophin stimulation. *Arthritis Rheum.*, 31:1314–1317.
- Danek J (2003). Effect of *Escherichia coli* endotoxin on the levels of testosterone and estradiol-17 β in blood serum and seminal plasma and on the semen characteristics in the stallion. *Bull. Vet. Inst. Pulawy* 47: 191–201.
- Fraczek M, Kurpisz M (2005). The redox system in human semen and peroxidative damage of spermatozoa. *Postepy. Hig. Med. Dosw.*, 59:523–534.
- Jégo B, Cudicini C, Gomez E, Stéphan JP (1995). Interleukin-1, interleukin-6 and the germ cell-Sertoli cell cross-talk. *Reprod. Fertil. Dev.*, 7:723–730.
- Huang H, Liu T, Rose JL, Stevens RL, Hoyt DG (2007). Sensitivity of mice to lipopolysaccharide is increased by a high saturated fat and cholesterol diet. *J. Inflamm.*, 4:22. doi: 10.1186/1476-9255-4-22.
- Kajihara T, Okagaki R, Ishihara O (2006). LPS-induced transient testicular dysfunction accompanied by apoptosis of testicular germ cells in mice. *Med. Mol. Morphol.*, 39:203–208.
- Kern S, Robertson SA, Mau VJ, Maddocks S (1995). Cytokine secretion by macrophages in the rat testis. *Biol. Reprod.*, 53(6): 1407–1416.
- Lei L, Ping M, Yongjun L, Chen H, Wai-Sum O, Tang F, Zhang JV (2013). Intermedin Attenuates LPS-induced Inflammation in the rat testis. *PLoS One*. 8: e65278.
- Li Z, Zhang D, He Y, Ding Z, Mao F, Luo T, Zhang X (2016). Lipopolysaccharide compromises human sperm function by reducing intracellular cAMP. *Tohoku J. Exp. Med.*, 238, 105–112.
- Ma XM, Lightman SL (1998). The arginine vasopressin and corticotrophin-releasing hormone gene transcription responses to varied frequencies of repeated stress in rats. *J. Physiol.*, 510(2): 605–614.
- Metukuri MR, Reddy CM, Reddy PR, Reddanna P (2010). Bacterial LPS mediated acute inflammation-induced spermatogenic failure in rats: role of stress response proteins and mitochondrial dysfunction. *Inflammation* 33(4): 235–243.
- Ochsendorf RF (1999). Infections in the male genital tract and reactive oxygen species. *Hum. Reprod. Update.*, 5:399–420.
- Reddy MM, Mahipal SV, Subhashini J, Reddy MC, Roy KR, Reddy GV, Reddy PR, Reddanna P (2006). Bacterial lipopolysaccharide-induced oxidative stress in the impairment of steroidogenesis and spermatogenesis in rats. *Reprod. Toxicol.*, 22: 493–500.
- Wang A, Fanning L, Anderson DJ, Loughlin KR (1997). Generation of reactive oxygen species by leukocytes and sperm following exposure to urogenital tract infection. *Arch. Androl.*, 39:11–17.
- WHO (2010). World Health Organization laboratory manual for the examination and processing of human semen. 5thed.WHO Press: Geneva. pp: 26–32.
- Winnall WR, Muir JA, Hedger MP (2011). Rat resident testicular macrophages have an alternatively activated phenotype and constitutively produce interleukin-10 *in vitro*. *J. Leukoc. Biol.*, 90(1): 133–143.